MICHIGAN RADIOLOGICAL SOCIETY

Resident & Fellow Section

15th Annual Resident Research Forum

Resident Conference Abstracts

25th Annual Resident & Fellow Section Confernece
February 11, 2022
Agenda

8:30 a.m. Breakfast

9:00 a.m. Introduction – Michelle Shnayder-Adams, MD, MPH, President, MRS Resident & Fellow Section

9:10 a.m. AI in Radiology & Career Transitions, Sonia Gupta, MD

10:15 a.m. Q & A

10:30 a.m. Self-Reflection and Goal Setting, Matthew Davenport ,MD

11:30 a.m. Advocacy & Legislative Issues, Robert H S. Schaffer, PC

12:30 p.m. Lunch

1:00 p.m. Break with Sponsors

1:30 p.m. Abstract Presentations

Courtney Cave M.D. , Henry Ford Hospital
Variability in Clinical and Imaging Follow-up of Pediatric Breast Masses

Adrien Nguyen, D.O., MSUCHM Ascension Providence Hospital 3D Tomosynthesis: Are we Missing Calcifications That Matter?

Alexandra Morris, M.D., Henry Ford Hospital
Increased Bleeding Risk After Image Guided Percutaneous Random Liver Biopsy in Patients Undergoing Workup for Cardiac Transplant

Kaitlin M. Zaki-Metias, M.D., St. Joseph Mercy Oakland
Breast Arterial Calcifications: Reporting Preferences and Impact on Screening for Coronary Artery Disease

2:30 p.m. Quiz Bowl

3:30 p.m. Announcement of 2022 Board Members

3:40 p.m. Adjourn

15th Annual Resident Research Forum Winners

Courtney Cave M.D.

Henry Ford Hospital

Variability in Clinical and Imaging Follow-up of Pediatric Breast Masses

Adrien Nguyen, D.O.

MSUCHM Ascension Providence Hospital

3D Tomosynthesis: Are we Missing Calcifications That Matter?

Alexandra Morris, M.D.

Henry Ford Hospital

Increased Bleeding Risk After Image Guided Percutaneous Random Liver Biopsy in Patients Undergoing Workup for Cardiac Transplant

Kaitlin M. Zaki-Metias, M.D.

St. Joseph Mercy Oakland

Breast Arterial Calcifications: Reporting Preferences and Impact on Screening for Coronary Artery Disease

Patch Technique for Primary Treatment of Type A Carotid Cavernous Fistula: Technical Notes and Outcomes



Anas S. Al-Smadi, M.D1; Rehan Ali, M.D1; Ari D. Kappel, M.D. 2, Osama Intikhab, M.D. 1, Gary B. Rajah, M.D2,3; Ali Luqman, M.D2

1. Department of Radiology, Wayne State University, School of Medicine, Detroit, MI,
2. Department of Neurosurgery, Wayne State University, School of Medicine, Detroit, MI, USA
3. Department of Neurosurgery, Munson Medical Center, Traverse City, MI, USA

Background: Type A Carotid Cavernous Fistulas (CCFs) are high-flow fistulas which can be difficult to treat. Conventional treatments have focused on cavernous sinus packing or embolization which can have mass effect related consequences. In this case series we describe utilizing our Patch Technique (PT) as the solo non-adjunctive treatment of Type A CCF with severe cortical venous reflux.

Methods: A retrospective review was performed for patients who underwent PT at our institution. Patients' demographics, clinical data, pre and post-operative ocular examination were recorded. The procedures technique, Pipeline Embolization Devices (PED) diameters, immediate and late procedure outcomes were described.

Results: Three male patients with age of 24, 29 and 62 years at the date of the first procedure. All patients had history of trauma and presented with decreased visual acuity, cranial nerve II deficit, limited extra-ocular muscles movement and increased intra-ocular pressure (IOP). Diagnostic angiography was performed which confirmed high flow type A CCF. Endovascular treatment was performed via distal radial access in 2 patients and femoral access in 1 patient by deploying four sequentially enlarging PEDs with immediate resolution of the ocular symptoms. Follow-up angiography confirmed complete resolution of CCF in 2 patients. One patient was lost to follow-up, however angiogram at 4 months demonstrated residual small CCF with significant improvement from post procedure angiogram.

Conclusion: The Patch-Technique utilizing sequentially enlarging flow-diverters is a safe and reasonable solo technique for the treatment of direct CCF symptoms and results in immediate resolution of CVR while preserving the cavernous sinus anatomy.



Courtney Cave M.D.

Variability in Clinical and Imaging Follow-up of Pediatric Breast Masses

Courtney Cave M.D., Elizabeth Dobben M.D., Jessica Leschied M.D., & Zeynep Yilmaz-Saab M.D.
Henry Ford Health System

Introduction: Pediatric breast masses are almost always benign with approximately 95% of them representing fibroadenomas. On ultrasound, these are classically described as circumscribed, oval, hypoechoic solid masses. The current proposed recommendations in the pediatric literature for managing these masses include follow up ultrasound for a mass <3 cm, core biopsy for a mass 3-5 cm, and surgical excision for a mass >5 cm. We sought to determine how often these guidelines were appropriately applied and if the interpreting radiologist subspecialty (ie. pediatric, breast, or general radiologist) had a significant impact on the type of follow up recommended.

Elizabeth Dobben M.D.

Methods: Following IRB approval, pediatric patients who received a breast ultrasound for a solid mass between 2017-2020 were identified by retrospective query of the electronic medical record. After completion of chart review this yielded 370 patients ranging in age from 9 to 18 years. 169 patients had a mass consistent with a fibroadenoma. The follow-up for these patients was categorized into clinical follow-up, ultrasound follow-up, core biopsy, or surgical excision. This data was further broken down by lesion size and nterpreting radiologist subtype.

Results: Of the 169 patients included in the study, 26.03% underwent 6-12 month imaging follow up, 40.2% received core biopsy, and 18.3% underwent excisional biopsy. 6.5% had clinical follow up without either further imaging or biopsy. The remainder of the patients were lost to follow up. Data was further stratified by mass size and interpreting radiologist subspecialty. This demonstrated variability in management among radiologist subspecialist. Additionally, the data showed that masses <3 cm are the most frequently mismanaged with 53% of these masses undergoing biopsy rather than ultrasound follow-up as per the guidelines ($p<0.00001$).

Conclusion: These findings indicate a significant number of pediatric patients at our institution undergo biopsy for lesions that should be managed more conservatively per guidelines. While multiple factors influence the decision to biopsy or surgically excise a mass, published literature shows that follow up sonography is a safe, non-invasive management strategy for masses with specific sonographic characteristics and size in this patient population. Despite this, only 26.03% of the pediatric breast masses in this study were managed with follow up sonography regardless of the interpreting radiologist subspecialty, with the majority undergoing core biopsy. Increased familiarity with the published management guidelines of pediatric solid breast masses would decrease the number of unnecessary procedures and improve consistency in follow up recommendations by radiologists.

Variability in Clinical and Imaging Follow-up of Pediatric Breast Masses Cont.

References:

Brownstone, ND, Celie, KB, Spigland, NA, Otterbum, DM. Pediatric Breast Fibroadenoma: A Systematic Review and Algorithm for Treatment. Ann Plast Surg. Nov 2019. 83(5):601-605.

Jayasinghe, Y, Simmons, PS. Fibroadenomas in adolescence. Curr Opin Obstet Gynecol. Oct 2009. 21(5):402-6.

Koening, JL, Davenport, KP, Poole, PS, Kruk, PG, Grabowski, JE. Breast Imaging-Reporting and Data System (BI-RADS) classification in 51 excised palpable pediatric breast masses. Journal of Pediatric Surgery. Oct 2015. 50(10):1746-50.

Omar, L, Gleason, MK, Pfeifer, CM, Sharma, P, Kown JK. Management of Palpable Pediatric Breast Masses with Ultrasound Characteristics of Fibroadenoma: A More Conservative Approach. J Roentgenol. Feb 2019. 212(2)450-455

Sanders, M, Sharma, P, Madany, M, King, A, Goodman, K, Sanders, A. Clinical breast concerns in low-risk pediatric patients: practice review with proposed recommendations. Pediatric Radiology. (2018)48:186-195.

Building on Resident Wellbeing with a Practical Wellness Curriculum

Kyle Dammeyer - Henry Ford Hospital

Purpose:
To create a curriculum geared towards improving resident wellbeing, job satisfaction, and mental and emotional preparation for starting a sustainable radiology career beyond residency.

Methods and Materials:
The radiology residency program's wellness committee created and organized a curriculum of 8 lectures which were given during the scheduled daily lecture time slot. Lecture material and topics were brainstormed by the committee and included topics on financial literacy/planning, navigating life and disability insurance, ergonomics at the workstation, medical malpractice, CV preparation, and career options as they relate to work-life balance. A survey was created prior to the start of the curriculum which assessed resident's overall wellness, their satisfaction with the program's commitment to wellness, and to what degree a wellness curriculum would improve their experience. This survey was then re-administered to the same classes of residents after completion of the curriculum.

Results:
On a scale from 1 to 5 (1 - least "well", 5 - most "well"), the mean score amongst all respondents with regards to assessing personal "wellness" was 3.77 prior to implementation of the curriculum and 4.04 following implementation, an increase of 0.27. The mean response to "satisfaction with the residency program's awareness of residency wellness and efforts to improve the overall resident experience" was 4.04 pre-implementation and 4.33 following implementation, an increase of 0.29. The mean response to "how much of a positive effect do you think an improved radiology resident wellness curriculum would have on your overall residency experience" was 3.54 pre-implementation and 3.78 following implementation, an increase of 0.24.

Conclusions:
Following the implementation of a radiology residency "wellness curriculum", residents responded with higher self-rated scores of wellness, increased satisfaction with the program's "awareness of wellness" and "efforts to improve the resident experience", and higher ratings of the potential for a wellness curriculum to have a positive effect on their "residency experience". These increased ratings, as well as free text comments in the survey, suggest that radiology residents' wellness can be improved with implementation of a more practical wellness curriculum.

Pneumomediastinum Complicating COVID-19 Pneumonia, a Case Report

Shahram Hadidchi M.D.

Shahram Hadidchi M.D., Krunal Moradiya BSc, Hamed Kordbacheh M.D.
Detroit Medical Center

Introduction:

Pneumomediastinum is a known complication of novel coronavirus disease 2019 (COVID-19). Spontaneous pneumomediastinum and traumatic pneumomediastinum are the two common etiologies 1,2,7. Spontaneous pneumomediastinum is more associated with COVID-19 2-7. Traumatic pneumomediastinum may occur from invasive and noninvasive ventilation-related barotrauma 1-3,7.

Case Report:

We present here a case of a 53 year old male patient admitted for COVID-19 pneumonia (Figure 1) who developed pneumomediastinum while he was on High Flow Nasal Cannula (HNFC) oxygen therapy. Two weeks after diagnosis, the patient had chest discomfort and worsening dyspnea. Chest radiograph (Figure 2) showed a small rim of air at the aorticopulmonary (AP) window and the left heart border suggestive of pneumomediastinum. Pneumomediastinum was confirmed with CT thorax (Figure 3). HNFC oxygen therapy was continued due to the patient's low oxygen saturations and his clinical condition slowly improved.

Discussion:

CT scan is highly sensitive for pneumomediastinum 2-7 but pneumomediastinum might be more difficult to diagnose in chest radiographs.

Radiographic features of pneumomediastinum include: 1) Lucency along the mediastinal contour or the heart borders. 2) Diaphragm border that continues across the left and right hemidiaphragm (continuous diaphragm sign). 3) Air anterior to the heart in the lateral view. 4) Subcutaneous emphysema and gas in the neck tissue. 5) Gas around pulmonary artery and main branches (ring around artery sign). 6) Air between the left lower lateral mediastinal border and medial left hemidiaphragm (Naclerio V sign). Being aware of this uncommon but important complication of COVID-19 and its radiographic findings is of great significance for radiologists.

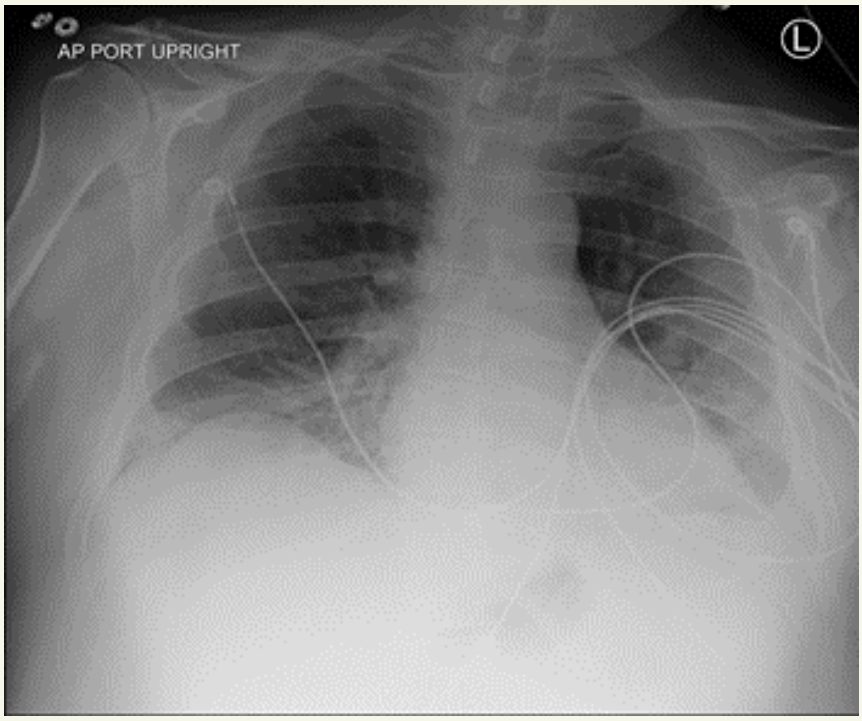

Figure 1: First chest radiograph demonstrates multifocal and bilateral airspace opacities with peripheral and basal predominance. No pneumothorax or subcutaneous emphysema is seen.

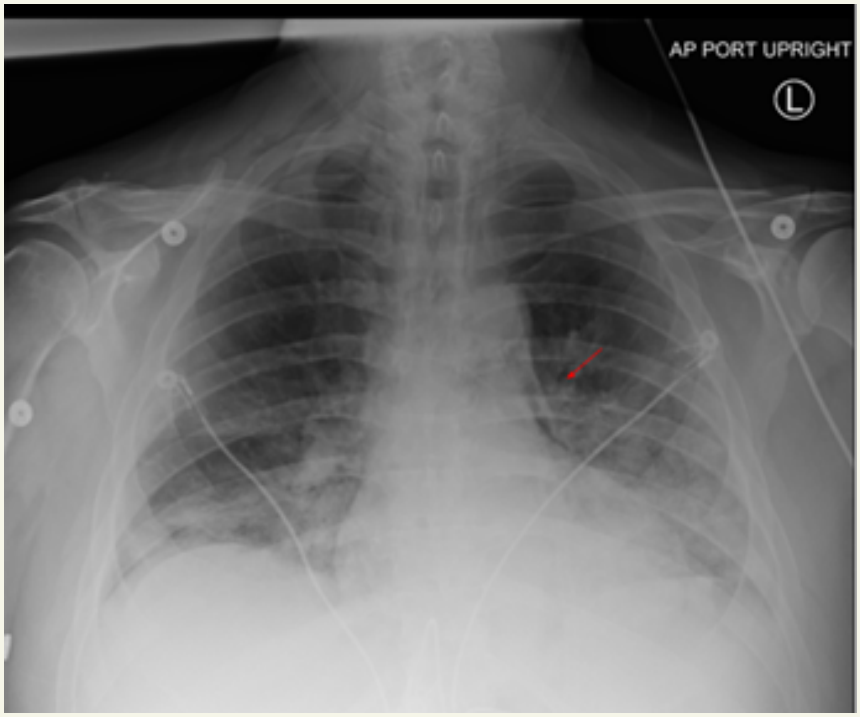

Figure 2: Chest radiograph two days later demonstrates bilateral basal and peripheral airspace opacification which has increased since the prior radiograph. There is a small rim of air at the AP window extending down the left heart border. Oblique strips of air in the lower neck represent subcutaneous emphysema.

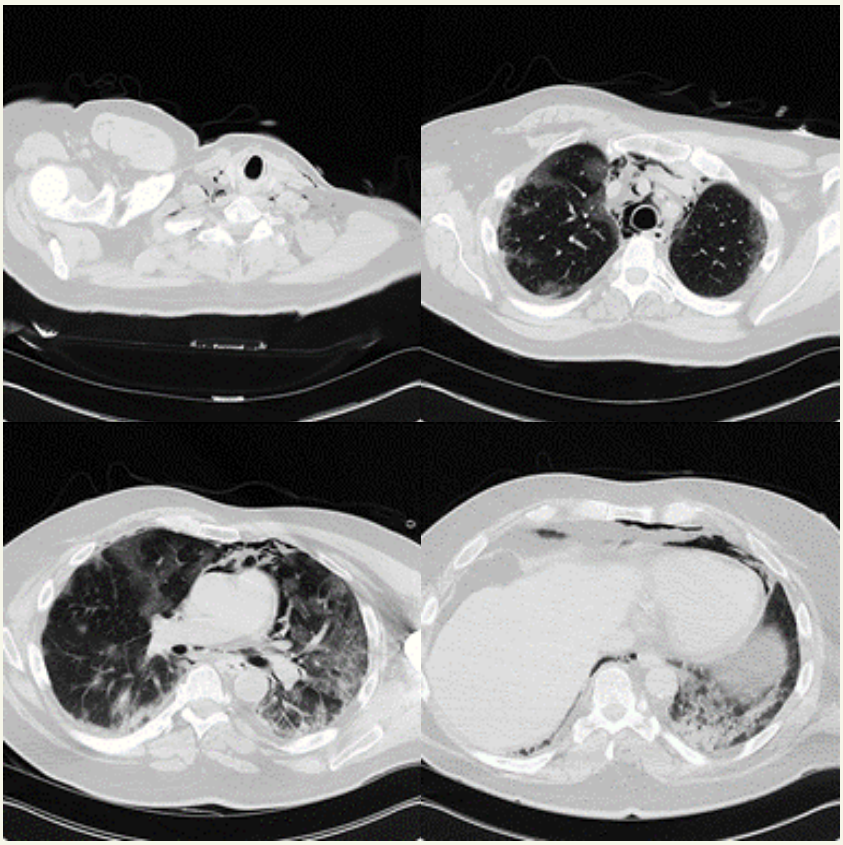

Figure 3: CT Thorax demonstrates multifocal ground glass opacification and consolidation throughout the lungs with peripheral and basal predominance in keeping with the patient's diagnosis of COVID-19 pneumonia. Additionally, pneumomediastinum and subcutaneous emphysema is seen as multiple locules of air in the mediastinum extending to the lower neck. No pneumothorax or interstitial emphysema is evident.

References:

1. Dissanaike S, Shalhub S, Jurkovich GJ. The evaluation of pneumomediastinum in blunt trauma patients. J Trauma. 2008 Dec;65(6):1340-5. doi: 10.1097/TA.0b013e318169cd24. PMID: 19077624.

2. Gutierrez-Ariza JC, Rodriguez Yanez T, Martinez-Ávila MC, Almanza Hurtado A, Dueñas-Castell C. Pneumomediastinum and Pneumothorax Following Non-invasive Respiratory Support in Patients With Severe COVID-19 Disease. Cureus. 2021 Oct 15;13(10):e18796. doi: 10.7759/cureus.18796. PMID: 34796074; PMCID: PMC8590743.

3. Mart, M. F., Norfolk, S. G., Flemmons, L. N., Stokes, J. W., Bacchetta, M. D., Trindade, A. J., Casey, J. D., Semler, M. W., Ely, E. W., & Noto, M. J. (2021). Pneumomediastinum in Acute Respiratory Distress Syndrome from COVID-19. In American Journal of Respiratory and Critical Care Medicine (Vol. 203, Issue 2, pp. 237–238). American Thoracic Society. https://doi.org/10.1164/rccm.202008-3376im

4. Goldman, N., Ketheeswaran, B., & Wilson, H. (2020). COVID-19-associated pneumomediastinum. In Clinical Medicine (Vol. 20, Issue 4, pp. e91–e92). Royal College of Physicians. https://doi.org/10.7861/clinmed.2020-0247

5. Sekhon, M. S., Thiara, S., Kanji, H. D., & Ronco, J. J. (2021). Spontaneous Pneumomediastinum in COVID-19: The Macklin Effect? In American Journal of Respiratory and Critical Care Medicine (Vol. 204, Issue 8, pp. 989–990). American Thoracic Society. https://doi.org/10.1164/rccm.202105-1179im

6. Chowdhary, A., Nirwan, L., Abi-Ghanem, A. S., Arif, U., Lahori, S., Kassab, M. B., Karout, S., Itani, R. M., Abdalla, R., Naffaa, L., & Karout, L. (2021). Spontaneous Pneumomediastinum in Patients Diagnosed with COVID-19: A Case Series with Review of Literature. In Academic Radiology (Vol. 28, Issue 11, pp. 1586–1598). Elsevier BV. https://doi.org/10.1016/j.acra.2021.07.013

7. Damous SHB, Dos Santos Junior JP, Pezzano ÁVA, et al. Pneumomediastinum complicating COVID-19: a case series. Eur J Med Res. 2021;26(1):114. Published 2021 Sep 26. doi:10.1186/s40001-021-00585-9

Venous Stenting of Iliocaval Thrombosis in the Treatment of Chronic Pelvic Pain

Hussam Hindi, D.O. - Wayne State University/DMC

Introduction: Chronic pelvic pain is a prevalent issue that affects roughly 15% of women in the US and is characterized as chronic noncyclical pelvic pain that lasts longer than 6 months. Pelvic congestion syndrome (PCS) is secondary to ovarian or parauterine vein incompetence causing dilation. Dilation can also be caused by external compression, May-Thurner syndrome, and Nutcracker syndrome. The diminished venous return presents as chronic dull pelvic pain/heaviness that is exacerbated by walking or upright posture. The most definitive imaging modality for diagnosis is venography, outlined as ovarian vein diameter >5 mm, free reflux in the gonadal vein, congested ovarian venous plexus with stagnation of contrast, filling of pelvic veins across midline and filling of thigh/vulvovaginal varicosities. Typically, this condition is treated endovascularly with ovarian vein embolization, however, the following unconventional case underscores the importance of understanding chronic pelvic pain and its possible etiologies.

Case Presentation: 50-year-old female with a history of Factor V Leiden and Protein S deficiency presents with severe pelvic pain and heaviness after prolonged standing. She rates the discomfort in her back, pelvis, and legs as a 10/10. A CT scan was obtained for further characterization which demonstrated a diminutive IVC with compensatory dilation of the left ovarian vein measuring 1.5 cm (Figure A) and multiple pelvic venous collaterals suggestive of pelvic congestion syndrome. The patient was taken to the angiography suite for possible intervention. Venogram after access of the right common femoral vein revealed stenosis and irregularity extending into the infrarenal IVC with extensive pelvic collaterals (Figure B). A Cobra C2 catheter was used to select the left renal vein and venogram of the ovarian vein showed antegrade flow of contrast without reflux (Figure C). Given that the enlarged left ovarian vein and was serving as a venous conduit to drain the lower extremities and there was no evidence of reflux, the ovarian vein was not embolized. Alternatively, attention was turned to reestablishing outflow through the inferior vena cava (IVC) and indirectly decompressing the ovarian vein and pelvic collaterals. The patient underwent IVC and right iliac vein serial balloon dilation up to 10 mm x 40 mm with right external iliac vein stent (12x60 mm Venovo) placement (Figure D) for residual stenosis. The decision was made to bring the patient back at a later date for further intervention. During the second procedure an intravenous ultrasound catheter (IVUS) was used demonstrating multiple areas of stenosis in the right iliac veins/IVC and segments of greater than 80% stenosis of the left iliac veins. Two Z stents (20 mm x 50 mm) were placed in the infrarenal IVC with overlapping kissing Venovo stents extending into the left external iliac vein (14 mm x 140 mm) and in the right (14 mm x 80 mm), overlapping the previously placed stent. Repeat venogram (Figure E) showed absent opacification of the pelvic venous collaterals and left ovarian vein with antegrade flow through the stent. The patient recovered without complication and was subsequently discharged. The patient was instructed to continue taking her prescribed 5mg of Eliquis daily and was started on 81mg Aspirin daily for antiplatelet therapy indefinitely. On subsequent follow up the patient had significantly reduced pelvic and leg pain and her discomfort decreased to a 5/10. She states her quality of life has tremendously improved.

Conclusion: Pelvic congestion syndrome is a complex, underdiagnosed condition that needs more consideration when treating chronic pelvic pain. Although this patient had dilated gonadal and pelvic veins and symptoms of pelvic pain, this not considered typical PCS secondary to the absence of reflux. The dilated veins act as a conduit for drainage and are more likely to become congested secondary to incompetent valves. This patient benefited from iliocaval reconstruction to decompress the ovarian and pelvic veins and resolve the patient's discomfort. Ovarian vein embolization in this setting would have worsened the patient's symptoms and removed her only outlet for decompression. Therefore, it is imperative to delineate the underlying cause of chronic pelvic pain before intervening.

References:

Till, Sara R et al. "Psychology of Chronic Pelvic Pain: Prevalence, Neurobiological Vulnerabilities, and Treatment." Clinical obstetrics and gynecology vol. 62,1 (2019): 22-36. doi:10.1097/GRF.0000000000000412

Bookwalter, Candice A et al. "Imaging Appearance and Nonsurgical Management of Pelvic Venous Congestion Syndrome." Radiographics : a review publication of the Radiological Society of North America, Inc vol. 39,2 (2019): 596-608. doi:10.1148/rg.2019180159

Venous Stenting of Iliocaval Thrombosis in the Treatment of Chronic Pelvic Pain Cont.

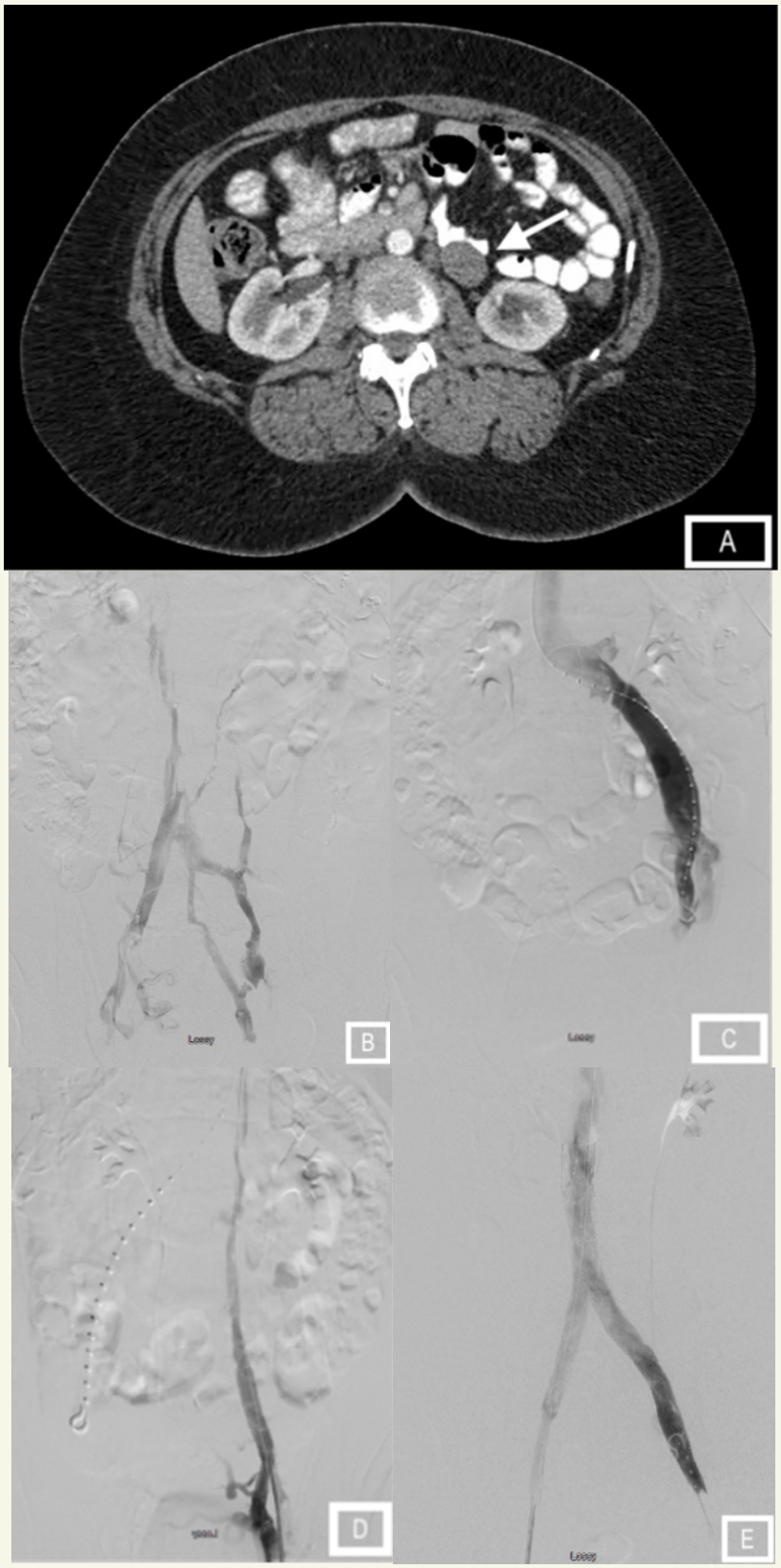

Increased Bleeding Risk After Image Guided Percutaneous Random Liver Biopsy in Patients Undergoing Workup for Cardiac Transplant

Alexandra Morris, MD

Alexandra Morris, MD, Todd Williams, MD, Daniel Myers, MD
Henry Ford Hospital, Department of Radiology

Introduction: Liver biopsies are commonly performed in cardiac transplant candidates to evaluate for fibrosis secondary to congestive hepatopathy, since there is a known relationship between the degree of fibrosis and transplant outcomes1,2. Patients undergoing image-guided (CT or ultrasound) percutaneous random liver biopsy as part of a cardiac transplant workup were observed to have a marked increased incidence of hemorrhagic post-procedure complications (20%) compared to patients undergoing liver biopsy for other indications (0.4%). Hemorrhagic post-procedure complications were defined as peritoneum and/or subcapsular hematoma identified at post-procedure imaging, which was performed based on clinical indications post procedure (e.g. increased abdominal pain, hypotension, tachycardia). The purpose of this study is to determine the incidence of post liver biopsy hemorrhage in the pre-cardiac transplant patients relative to other patient populations and propose a new safety protocol to reduce the bleeding risk in these patients. By assessing various factors that may contribute to an increased bleeding risk in this patient population and reviewing the effects on outcomes after proposed safety measures are implemented, we will be able to propose new guidelines for liver biopsy in this specific patient population.

Methods: An IRB approved retrospective database review of all patients who underwent percutaneous image guided liver biopsy between 1/1/19 and 12/31/20 was performed and the hemorrhagic complication rate in pre-cardiac transplant patients versus the complication rate in patients undergoing liver biopsy for any other indication was tabulated. A collaborative risk mitigation process involving cardiology, cross-sectional interventional radiology, and vascular interventional radiology was instituted in an effort to reduce the hemorrhagic complication rate. These strategies were employed and complication rates in this subset of high-risk patients after the implementation of the safety protocols were recorded and compared.

Results: In patients undergoing percutaneous liver biopsy for all indications other than evaluation for cardiac transplant, the hemorrhagic complication rate overall was 0.4% (5/1225). In patients undergoing a liver biopsy as part of the workup for a cardiac transplant, the hemorrhagic complication rate was substantially higher at 20% (5/25). We believe this is likely due to patient comorbidities, including elevated right heart pressures and anticoagulation requirement.

Increased Bleeding Risk After Image Guided Percutaneous Random Liver Biopsy in Patients Undergoing Workup for Cardiac Transplant Cont.

We implemented multiple measures to reduce the risk of bleeding complications in these patients. These included, flagging high risk patients through orders in the EMR to alert the interventional team (specifically identify patients as pre-cardiac transplant as opposed to history of "evaluate for fibrosis"), scheduling biopsies in the morning to allow for extended post-procedure monitoring and if needed, further intervention during daytime hours, holding anticoagulation prior to the procedure according to the SIR consensus guidelines for high risk procedures4, and performing routine placement of a 5 mL gelfoam slurry at the biopsy site. Additionally, only a single 18-gauge core sample was obtained for pathology evaluation since all prior bleeding complications occurred with two or more 18-gauge core samples. Furthermore, transjugular liver biopsies were performed in patients with proven elevated right heart pressures.

Since implementing the safety measures, 6 liver biopsies have been performed in patients undergoing workup for cardiac transplant, 5 percutaneous and 1 transjugular. No hemorrhagic complications were observed in these patients.

Conclusions:
We have identified pre-cardiac transplant patients as having a significantly higher risk of hemorrhagic complications after image-guided percutaneous liver biopsy compared to patients undergoing liver biopsy for any other reason. We have designed and implemented a safety protocol to reduce complications from this procedure in this high-risk group.

References:
1. Tolia, S. Liver biopsy as a predictor for risk stratification in heart transplant candidates. J Am Coll Cardiol. 2021, May, 77.
2. Givertz, M. Assessing the liver to predict outcomes in heart transplantation. Journal of Heart and Lung Transplantation, 2015, July; 34(7).
3. Midia, M., Odedra, D., Shuster, A., Midia, R., and Muir, J. Predictors of bleeding complications following percutaneous image-guided liver biopsy: a scoping review. Diagn Interv Radiol, 2019, Jan; 25(1): 71-80.
4. Patel, I., Rahim, S., Davidson, J.C., et. Al. Society of Interventional Radiology consensus guidelines for the periprocedural management of thrombotic and bleeding risk in patients undergoing percutaneous image-guided interventions – Part II: Recommendations. J Vasc Interv Radiol, 2019, June.



Adrien Nguyen, DO

Anicia Mirchandani, MD

3D Tomosynthesis: Are we missing calcifications that matter?

Author: Adrien Nguyen, DO1, Anicia Mirchandani, MD2, Evita Singh, MD1, Zaiba Mapkar, MD1, Sumita Joseph MD 1

1. Ascension Providence Hospital- Southfield, Department of Radiology
2. Wayne State University/Detroit Medical Center, Department of Radiology

Purpose

In the early detection of breast cancer, accurate identification of microcalcifications is essential. Although the advent of 3D-tomosynthesis was advantageous for other mammographic findings, its questionable reliability of detecting microcalcifications as compared to full-field digital mammography (FFDM) prompted the use of tomosynthesis concurrent with separate 2-D imaging for routine screening protocols. A synthesized view in which a 2D image is reconstructed from a 3D dataset could potentially negate the need for additional 2D image acquisition. Our study assessed the diagnostic values of 3D-tomosynthesis with synthesized views in terms of microcalcifications detection.

Materials and Methods

All stereotactic biopsies performed four years before (2011-2014) and four years after (2017-2020) implementation of 3D breast tomosynthesis (without a separate 2D mammogram) were retrospectively reviewed. Data from transitioning years of 2015-2016 prior to full implementation were excluded. Only those biopsies performed for micro-calcifications were analyzed and the results were categorized as benign, high-risk benign, and malignant. Biopsy cases missing relevant information were excluded. The overall numbers and percentages of biopsies and subcategories were compared before and after implementation of 3D-tomosynthesis. Proportional comparisons were performed via MedCalc software including N-1 Chi-squared tests and 95% confidence interval (CI) calculations.

Results

From 2011-2014, prior to the use of 3D-tomosynthesis at our institution, 141685 screening exams resulted in 1482 stereotactic biopsies, of which 849 (57.29%) were for calcifications. These biopsies yielded 658 benign (75.50%), 99 high-risk benign (11.66%), and 92 malignant (10.84%).

From 2017-2020, after the use of 3D-tomosynthesis, 136824 screening examinations resulted in 1417 stereotactic biopsies, of which 746 (52.65%) were performed for calcifications. These biopsies yielded 509 benign (68.23%), 124 high-risk benign (16.62%), and 113 malignant (15.15%).

There was a 0.05% decrease in biopsy rate for calcifications per total screening ($p=0.59$, CI = -0.0002% - 0.112%). A 7.27% decrease in benign biopsy rate was observed ($p<0.0001$, CI=4.93% - 13.65%). The high-risk benign and malignant biopsy rates both increased, with respective values of 4.96% ($p=0.0084$, CI=1.48% - 8.37%) and 4.31% ($p=0.0104$, CI = 1.00 - 7.65%).

Conclusion

The introduction of 3D tomosynthesis has been widely adopted , but there is a concern regarding its accuracy for microcalcifications detection in comparison to FFDM. Our results support that 2D synthesized views constructed from 3D datasets not only significantly increase the detection of malignant and high risk microcalcifications but also decrease unnecessary false positive biopsies. Therefore, the need for separate 2D imaging acquisition could be safely eliminated.

Clinical Relevance Statement.

In support of recently published articles, our study reinforces the values of synthesized views fulfilling the clinical requirements of FFDM with the benefits of decreasing radiation exposure, establishing safe transition to solely 3D-tomosynthesis screening, and maintaining if not improving the diagnostic utility of detecting microcalcifications.

Trauma Imaging in Pregnancy: CT Mimics of Placental Injury

Kaitlin M. Zaki-Metias, MD

Kaitlin M. Zaki-Metias, MD, Mehrvaan Kaur, MD, Huijuan Wang, MD, Nicholas Mills, MD, Bilal Turfe, Yanruo Lu, MD, Bashir H. Hakim, MD, Leslie S. Allen, MD

Department of Radiology, St. Joseph Mercy Oakland Hospital, Pontiac, MI

Introduction: Blunt abdominopelvic trauma in pregnant women can be a cause of great concern for both the mother and the fetus. The fetus should always undergo sonographic evaluation and monitoring to assess for signs of distress or fetal demise. Cross-sectional imaging should be used judiciously, as radiation doses emitted by computed tomography increase the risk of harm to the fetus and future development of childhood cancers.

Case Summary: A 37-year-old pregnant female at 34 weeks and 4 days gestation presented to the emergency department following a motor vehicle collision with blunt abdominal impact. Bedside ultrasound performed by the obstetrician demonstrated good fetal heart tones and normal amniotic fluid index. Due to the history of blunt abdominopelvic trauma, CT of the chest, abdomen, and pelvis was obtained after discussion of benefits and risks with the patient by the emergency department physician, obstetrician, and trauma team. Contrast-enhanced portal venous phase CT demonstrated multiple hyperdense foci within an anteriorly located fundal placenta. The findings were discussed with the on-call obstetrician and were determined to be normal placental venous lakes. The patient was monitored by the obstetrics team and was subsequently discharged home in stable condition.

Discussion: The CT appearance of a normal placenta will evolve with the progression of the pregnancy. Given the evolving nature of the placenta, there are imaging features of the placenta on CT that can be misinterpreted for placental injury. In the first trimester, the placenta is almost indistinguishable from the myometrium, with a homogenous appearance and indistinguishable smooth chorionic plates along the periphery of the uterine cavity. Throughout the second trimester, the placenta becomes heterogeneous in appearance and increases in attenuation relative to the myometrium. Of note, it is during the second trimester that placental cotyledons start forming and are featured as low attenuation throughout the placenta. Chorionic plate indentations may begin to be visualized by the late second or third trimester appearing as hypoattenuating indentations at the interface of the placenta and the uterine cavity. By the third trimester, the placenta appears increasingly heterogeneous with better visualization of the venous lakes. Venous lakes often appear as areas of contrast blush on the maternal side of the placenta and can be mistaken for placental hemorrhage or abruption.

Trauma Imaging in Pregnancy: CT Mimics of Placental Injury Cont.

Conclusion: Given the high mortality rate of nonobstetric trauma to both the mother and the fetus, CT should be utilized after discussion of the risks and benefits with the patient and care team. CT provides improved anatomic detail compared to ultrasound and is superior to MRI in terms of time required to complete the examination and timely availability. The imaging appearance of the placenta evolves throughout pregnancy; radiologists may not be aware of the expected CT findings of a normal placenta as CT is rarely obtained in pregnancy. Radiologists should be aware of the evolving appearance of the normal placenta so as not to confuse the findings with those of placental injury.

Breast Arterial Calcifications: Reporting Preferences and Impact on Screening for Coronary Artery Disease

Kaitlin M. Zaki-Metias, MD, Jeffrey J. MacLean, MD, Paul A. Mergo, MD, Barakat Ogunde, MD, Mohammed Al-Hameed, MD, Cory Z. Trivax, MD

Department of Radiology, St. Joseph Mercy Oakland Hospital, Pontiac, MI

Introduction: Breast arterial calcifications (BAC) have been shown to correlate with measures of coronary artery disease risk stratification, although reporting of BAC is optional by BI-RADS guidelines. The purpose of this study is to determine referring provider preferences in BAC reporting on mammography reports and if such reporting has any impact on patient management.

Methods: A voluntary eight-question survey regarding the preferences and outcomes of BAC reporting on mammography was distributed to 1085 primary care physicians, obstetrics & gynecologists, medical oncologists, and breast and general surgeons in our health system via a secure online platform. Data analysis including Pearson Chi-square was performed with a P -value of < 0.05 for significance.

Results: A response rate of 19.1% (207/1085) was attained, with 21/207 (10.1%) of respondents indicating they do not routinely order mammograms excluded from further analysis. A total of 62.4% (116/186) of ordering physicians indicated a preference for reporting of BAC in both the body and impression of the radiology report, with 82.3% (153/186) of respondents placing importance on the quantity of atherosclerotic calcifications. Most participants (79.6%, 148/186) reported that the presence of BAC would prompt further investigation for coronary artery disease and associated risk factors.

Conclusion: The majority of responding physicians indicated a preference for detailed reporting of BAC and that such reporting would impact patient care. Understanding referring provider preferences regarding ancillary findings of BAC will allow for improved communication and value in mammography.

Thanks to our sponsors!

Advanced Radiology Services

Dr. Harris, Birkhill, Wang, Songe and Associates, PC

Huron Valley Radiology

Michigan Radiological Society Foundation

Southfield Radiology Associates